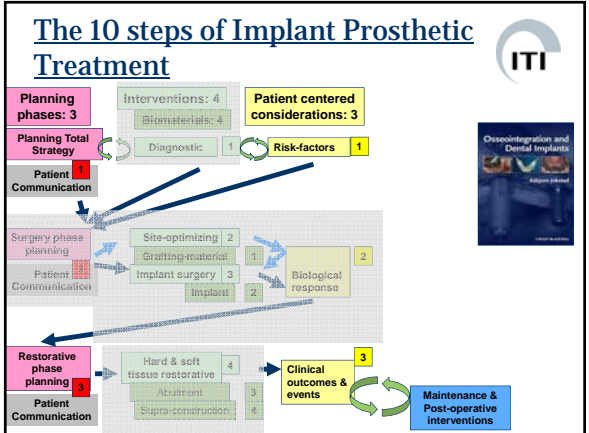


ITI International Team
 for Implantology


Early & Immediate loading of Oral Implants

Asbjørn Jokstad, DDS, PhD
 Professor and Head, Prosthodontics
 Faculty of Dentistry, University of
 Toronto

Holland Bloorview ITI Education Week
 October 27, 2010



SETTING



Doris and Harry were both provided with conventional prostheses many years back. Both call you and inform that they've been advised by a periodontist that all teeth need to come out due to refractory chronic periodontitis. Appointments are booked....

Clinical examination

"Doris"
 (Age 54)

"Harry"
 (Age 84)

1. Planning Total Strategy → 2. Diagnostic tests → 3. Risk-factors

Diagnostic Tests

"Doris"
 (Age 54)

"Harry"
 (Age 84)

1. Planning Total Strategy → 2. Diagnostic tests → 3. Risk-factors

10 yrs → 18 yrs

"Doris"
 (Age 54)

"Harry"
 (Age 84)

1. Planning Total Strategy → 2. Diagnostic tests → 3. Risk-factors

Provisional treatment: Extractions & interim denture

ITI

Evaluation of biological response after interim denture period before planning the surgery phase

"Doris" "Harry"

1. Planning Total Strategy → 2. Diagnostic tests → 3. Risk-factors → 5. Site optimize? (via Step 4. Surgery phase planning)

Planning for the surgery phase

"Doris": Delayed loading – One stage approach
"Harry": Immediate loading

1. Planning Total Strategy → 2. Diagnostic tests → 3. Risk-factors → 5. Site optimize? (via Step 4. Surgery phase planning)

Surgery Interventions- The surgery techniques

"Doris" (delayed loading) "Harry" (immediate loading)

Which implant system?

ITI

Planning for the Restorative phase

FIXED PROSTHESIS BASES: Fixed bar, Fusion bar, Metal bar, Full System


REMOVABLE PROSTHESIS BASES: Paris type bar, Round bar, Double bar, Metal bar, Milled bar, Hybrid bar

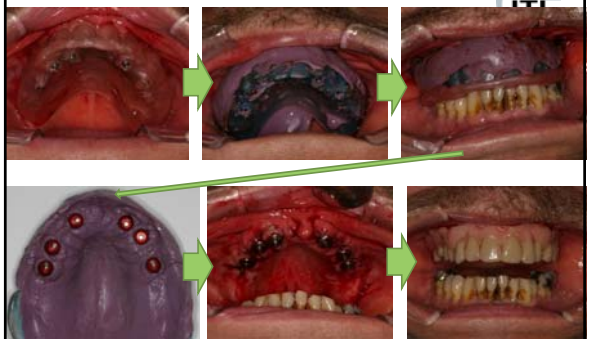
Restorative phase commencement 




"Doris" (delayed loading):
7 AstraTech implants with healing abutments

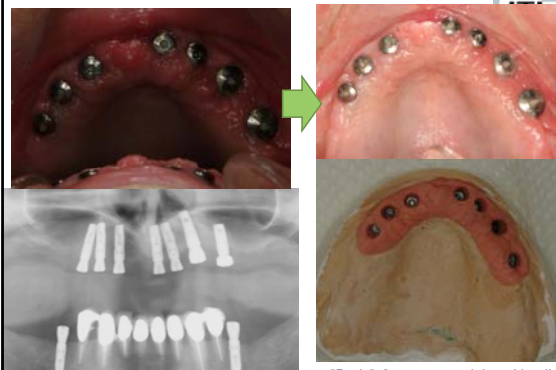
"Harry" (immediate loading):
6 Straumann implants with Open tray impression pins

Restoration of hard and soft tissues – Immediate loading 



"Harry" → immediate loading

Restoration of hard and soft tissues – delayed loading 



"Doris" → one-stage delayed loading

Restoration of hard and soft tissues – jaw relationships 



Establish vertical & horizontal relationships


Verify tooth placement, vertical & horizontal


"Doris" → one-stage delayed loading

Design&material for abutment, meso-structure and retention? 



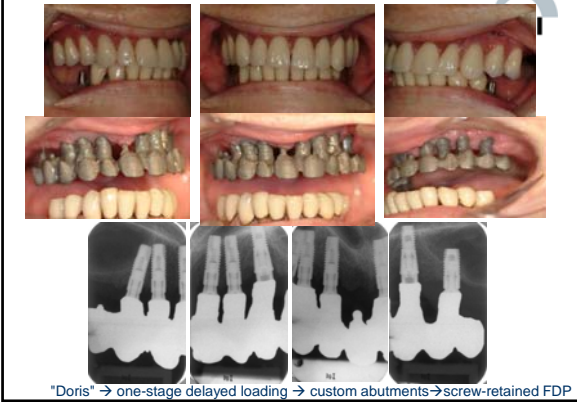"Doris" → one-stage delayed loading → abutments?

Restorative interventions – fabricate and fit abutment 

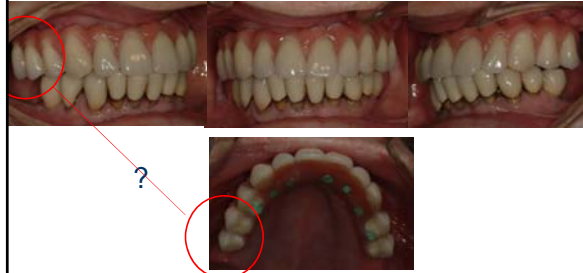

"Doris" → one-stage delayed loading → custom abutments

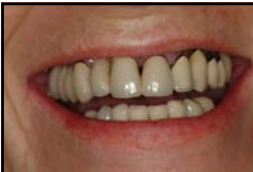Restorative intervention - fabrication and fit of supra-structure



Restorative intervention outcomes and prognosis



"Doris" → one-stage delayed loading → custom abutments → screw-retained FDP



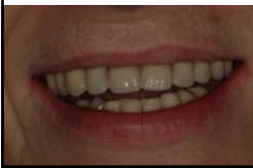Evaluation of the final outcome



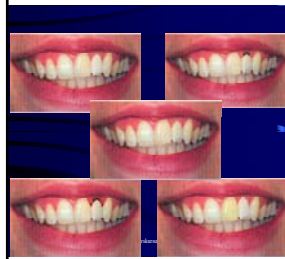Baseline - Edentulous	3 mths
Edentulous - Implant	6 mths
Implant - Healing	6 mths
Healing - Fabrication	2 mths

Focus on patient centered and not on surrogate criteria!:

1. Esthetics
2. Satisfaction
3. Quality of life
4. Function



Maintenance and possible follow-up interventions



- Routines
- Diagnostic protocols
 - Clinical
 - Radiographic
- Corrections of:
 - Papilla defect
 - Soft tissue correction
 - Local bone defect
 - Peri-implantitis
 - Post-sensitivity